

Research documents for AWG quantum treatment

〈 Disease 〉

Stomach cancer 1

〈 Symptoms 〉

Cancer pain, gastric ulcer, hypercholesterolemia, skin pigmentation, cachexia, Alzheimer's disease, hypoproteinemia, severe nausea and excessive vomiting, loss of appetite, diabetes

Name : ○o ○ura

Sex : Male

Age : 78 y.o.

Clinic/Doctor : S clinic

〈 History before and after AWG treatment 〉

He was hospitalized at Kindai University Hospital on the 28th of December, 2017. He was diagnosed with stomach cancer and was receiving chemotherapy by drips.

His first visit to our clinic was on the 26 of Jan, 2018.

In the first consultation, he was having pain in his stomach. After his first AWG treatment, he stated that the pain had gone.

In the second consultation on the 2nd of Feb, 2018, the pain was completely gone.

He tended to forget what had been said to him as he was suffering from dementia. It may be possible he has no recollection that he underwent chemo therapy at Kindai University Hospital from the 16th Feb.

He continued the AWG treatment from the 15th of Mar. He said that he felt so much better after the treatment.

We measured changes in blood glucose by glycated albumin instead of HBA1c as he has anemia.

The protocol of AWG treatment :

Immunity increase 7012 39 mins

Acidosis improvement 7003 36 mins

*Alternately run these 2 codes above

Escherichia coli 7032 27 mins

Gastritis 7137 42 mins

Cancer (EB virus) 7115 45 mins

Staphylococcal 7289 30 mins

Alcoholism 7010 24 mins

Pinworm, Pinworm 7249 36 mins

Total 291 mins (with 7012 immunity increase) / 288 mins (with 7003 acidosis improvement)

Oral medication :

Simvastatin (5) 1T1xafter breakfast, angiogenesis inhibitor

Cynal 4T2xafter breakfast and dinner, for adrenal function improvement

Hythiol (80) 2T2xafter breakfast and dinner, for adrenal function improvement

Ecabet sodium 3g2xafter breakfast and dinner, for urease function improvement

Takecab tablets (10) 1Cap1xafter breakfast, for stomach acid secretion control

He continuously takes CPL supplement 10g/day every day.

〈 Disease 〉

Stomach cancer 2-1

〈 Symptoms 〉

Cancer pain, Gastric ulcer, hypercholesterolemia, skin pigmentation, cachexia, hyper LDH syndrome, taste disorder, hypoproteinemia, edema of legs, severe nausea and excessive vomiting, loss of appetite, zinc deficiency, borderline diabetes

Name : Okazu Ohashi

Sex : Male

Age : 65 y.o.

Clinic/Doctor : S clinic

〈 History before and after AWG treatment 〉

He felt his stomach condition was unwell around Dec 2017. He eventually became unable to have meals and go to work. There were a significant weight loss and having night sweats.

Several abnormalities including high blood pressure were detected by company's annual general health checkup at Kindai University Hospital on the 17th Jan, 2018. He then visited a gastroenterology in his neighborhood and GI malignancy was strongly suspected. The doctor suggested him go back to the university hospital. However, he knew that, the conventional treatment methods (surgery, chemo therapy, and radiation therapy) would give his body a lot of stress. After watching our video, he decided to come to us for a first consultation on the 26 Jan, 2018.

In the first consultation, he claimed that he has a strong pain in his stomach. However, the pain was reduced significantly after a first AWG treatment.

At the second consultation on the 16 Feb, 2018, the stomach pain still remained, although it was self-controllable. The pain went away after the second AWG treatment.

When I met him at the third consultation, he stated the stomach pain had completely disappeared, however he continues the treatment as he still suffers from severe edema of his legs. The treatment seems to make him feel better.

He has left his job temporarily and is focusing on his health.

Weight loss : He claims that there was 5 kg of weight loss in one year and a half.

〈 Disease 〉

Gastric cancer 2-2

〈 Symptoms 〉

Cancer pain, gastric ulcer, hypercholesterolemia, skin pigmentation, cachexia, hyper LDH syndrome, taste disturbances, hypoproteinemia, edema of legs, severe nausea and excessive vomiting, loss of appetite, zinc deficiency, borderline diabetes

Name : Okazu Ohashi

Sex : Male

Age : 65 y.o.

Clinic/Doctor : S clinic

〈 History before and after AWG treatment 〉

The protocol of AWG treatment :

Immunity increase 7012 39 mins

Acidosis improvement 7003 36 mins

*Alternately set these 2 codes above

Escherichia coli 7032 27 mins

Gastritis 7137 42 mins

Cancer (EB virus) 7115 45 mins

Staphylococcal 7289 30 mins

Alcoholism 7010 24 mins

Pinworm, Pinworm 7249 36 mins

Ascites/Adema 7300 45 mins

Total 336 mins (with 7012 Immunity increase)

/ 333 mins (with 7003 acidosis improvement)

Oral medication :

Simvastatin (5) 1T1x after breakfast, angiogenesis inhibitor

Cynal 4T2x after breakfast and dinner, for adrenal function improvement

Hythiol (80) 2T2x after breakfast and dinner, for adrenal function improvement

Celecox (100) 2T2x after breakfast and dinner, to inhibit angiogenesis

PromacD (75) 2T2x after breakfast and dinner, to support zinc deficiency

Rebamipide 3T3x after every meal, gastric mucosal protection

Takecab tablets (10) 1Cap1x after breakfast, gastric acid secretion inhibition

Intravenous fluids through venous line (in the first session only) :

Amizet 400ml + Daivitmix 1A + ascorbic acid 1A + Primperan 1A + Novamin 1A

〈 Disease 〉

Gastric cancer 3

〈 Symptoms 〉

Cancer pain, gastric ulcer, hemorrhagic anemia, hypoproteinemia

Name : Oe Omoto

Sex : Female

Age : 62 y.o.

Clinic/Doctor : S clinic

〈 History before and after AWG treatment 〉

She was diagnosed with terminal gastric cancer on the 5th of July, 2017. She had a bypass surgery and is also suggested peritoneal dissemination. She chose home remedy as she started to be able to eat slowly without help.

She consulted us about her low-grade fever at 37.0°C (normally 36.2°C, She had a loss of appetite and epigastric pain on the 5th Jul, 2017. On the same day, she had her first AWG treatment.

We conducted the treatment again on the 14th Oct, the pain was relieved but it came back as time passed. Consequently, she was unable to come to the clinic so she switched to home treatment and rented a portable AWG device.

At the same time, she started to take OxyContin which was prescribed at Kindai University Hospital.

No contact from her since the last report that the pain has been reduced by the portable device.

She stopped taking CPL (Cyclic Poly Lactate) supplements, that she had been taking from 5/Oct/2017.

The protocol of AWG treatment :

Immunity Improvement	7012	39 mins
----------------------	------	---------

Acidosis improvement	7003	36 mins
----------------------	------	---------

*Alternately set these 2 codes above

Viral diseases	7324	36 mins
----------------	------	---------

Cancer (EB virus)	7115	45 mins
-------------------	------	---------

Cancer (Sarcoma)	7057	18 mins
------------------	------	---------

Cancer (Viral)	7064	12 mins
----------------	------	---------

Cancer (General)	7058	6 mins
------------------	------	--------

Cancer (Scirrhou)	7059	9 mins
-------------------	------	--------

Purification of blood and lymph plasma	7251	9 mins
--	------	--------

Total 174 mins (with 7012 Immunity increase)

/ 171 mins (with 7003 Acidosis improvement)

Oral medication :

Simvastatin (5) 1T1x after breakfast, angiogenesis inhibitor

Voltaren (25) 3T3x after every meal, disturbing neovascularization, improving in pain

Linzess (0.25) 2T1x before dinner, constipation improvement

〈 Disease 〉

Breast Cancer

〈 Symptoms 〉

Cancer pain, bone metastases, skin pigmentation

Name : Ooko Ota

Sex : Female

Age : 68 y.o.

Clinic/Doctor : S clinic

〈 History before and after AWG treatment 〉

Breast cancer was strongly suspected based on echo, mammography and MRI taken on Feb 3, 2010. HER2 – ER+ PgR+ were confirmed by needle biopsy on Feb 15.

March 24, surgical operation on the right breast, no signs of lymph node metastasis. May 13, 2015, L2 bone metastases was detected by MRI.

She underwent CyberKnife treatment x 5 times from 25 Jun to 1 Jul in the same year but it did not work on the pain from lumbar spine. She started taking Tramadol (opioid drug), although the pain still did not go away.

The L2 bone metastases was still confirmed by PET taken on the 13 August 2015.

In addition to that, metastasis of L4 and L5 spinal process were also found by other testing/checkups and later PET.

She started the AWG treatment from the 20th of Jan, 2017. Over the total of 6 times of the treatments, which were carried out on 20Jan, 24Jan, 2Feb, 9Feb, 20Feb and 7Mar, the pain from lumbar spine disappeared and the metastases could not be found on PET which was taken on 1 Jul in 2017.

She switched Tramadol to CPL (Cyclic Poly Lactate) supplements from the 4th Sep 2015. It may have supported to relieve the pain.

The protocol of AWG treatment :

Alternately set the codes of "Immunity increase 7012 39 mins"
and "Acidosis improvement 7003 36 mins"

Low-back pain 7201 39 mins

Lumbar spine 7202 24 mins

Breast cancer 7044 27 mins

Breast general 7289 9 mins

Total 123 mins (with Immunity increase code)

or 120 mins (with Acidosis improvement code)

Oral medication :

Cynal 4T2x after breakfast and dinner to improve adrenal function

Hythiol (80) 2T2x after breakfast and dinner to improve adrenal fatigue

Juvela N (200) 3Cap3x after every meal to improve peripheral circulatory

〈 Disease 〉

Prostate cancer

〈 Symptoms 〉

Cancer pain, Gastric ulcer, Hypercholesterolemia, borderline diabetes,
Essential hypertension

Name : Oaki Ota

Sex : Male

Age : 59 y.o.

Clinic/Doctor : S clinic

〈 History before and after AWG treatment 〉

A slight difficulty with urination, urethral pain and a high level of PSA which was at 16.2 were confirmed on the 17th Nov 2016. On the 21st Nov, he thread a balloon catheter at Kindai University Hospital, but the burning sensation remained in the urethra.

He started to take CPL supplements since the day of the catheter operation.

He underwent the AWG treatment on the 21 Jan, 28 Jan, 6 Feb, 25 Feb, 1 Mar and 6 Apr in 2017, total of 6 treatments. He stated his pain went away straight after the first treatment.

He stopped AWG as his PSA level went down.

He told us he feels a lot better after the AWG treatment.

The protocol of AWG treatment :

7012 Immunity increase 39 mins

7003 Acidosis improvement 36 mins

*Alternately set these 2 codes above

7324 Virus General 36 mins

7257 Prostate 21 mins

7318 Tumors (All) 24 mins

Total 120 mins (when 7012 Immunity increase)

/ 117 mins (when 7003 Acidosis improvement)

Oral medication :

Simvastatin (5) 1T1 × after breakfast, anti-angiogenic drugs

Captopril (25) 1T1 × after BF and dinner, hypertension improvement

Avolve 1Cap1×after breakfast for benign prostatic hyperplasia improvement

CPL supplement 10g/day (3g/day after PSA level decrease)

〈 Disease 〉

Non-tuberculous mycobacteria

〈 Symptoms 〉

8 Apr, 2005(H17) Initial diagnosis

He received 2 dental implants installed in 6 and 7 at the lower right a few years ago. Ever since the implants installation, there has always been tooth mobility and biting difficulty. On the 23rd May 2005, he removed the crowns and installed 1 artificial dental root inbetween 6 and 7.

Name : S.T.

Sex : Male

Age : 64 y.o.

Clinic/Doctor :
Nishihara Institute

〈 History before and after AWG treatment 〉

Jun 2012 (H24)

We performed a flap operation to the lesion 6 and 7.

The bone was damaged to a waterfall basin form as shown in pictures on the following pages.

Usually, dental implant has to be installed so the bone remodeling occurs in a non-infectious condition.

With his case, bone mineral was lost as if it was decalcified by strong acids and covered by connective sceroprotein tissue only. Refer to the pictures on the following pages.

11 May, 2015 (H27)

He visited our clinic after being diagnosed with tuberculous mycobacteria at a different medical institution.

We conducted a flap operation to the same lesion and filled with hydroxyapatite granules and also prescribed anti biotics. We looked at the tissue of the lesion with electro microscopy. As shown in the pictures on the following pages, the same bacteria to the one at the lesion of the lung was found. The lung completely cured by the anti-biotics.

In 2005, the bone in the operated lesion seemed that the bone was remodeled intact and its surrounding tissue was also normal, refer to the pictures on the following pages.

Regarding “the destroyed bone tissues accompanied by dental implant”, as “Rigid vs Rigid” this system doesn’t meet engineering theory. Destructive bone remodeling will be led by physical stress. Consequently, the bone becomes decalcified and it causes a critical inter-cellar infection to the remaining connective tissues.

〈 Disease 〉

Melanoma 1 (Intracellular infectious disease)

〈 Symptoms 〉

An infection on the skin, later becomes a melanoma (intercellular infectious disease)

If resection margins are remaining, there is a risk of a recurrence such as tumors

Name : N.K.

Sex : Male

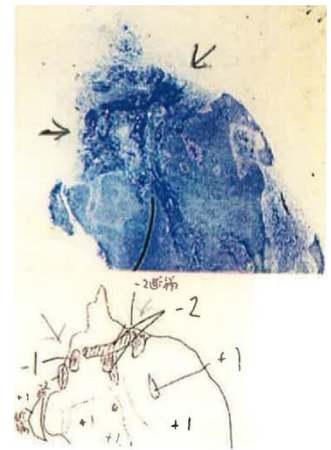
Age : ? y.o.

Clinic/Doctor :
Nishihara Institute

〈 History before and after AWG treatment 〉

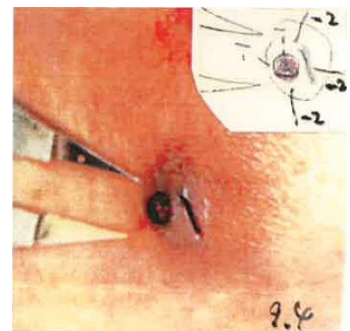
Jun 2012 (H24)

- 27Jul An infected black spot was found on the skin and surgically removed.
A microscopic image(right) of a slice of the lesion removed
arrows spotted area,
BDORT (BI-DIGITAL O-RING TEST)'s result (+)



30Aug A recurrence

4Sep BDORT's result, -2 (by microscopic images)



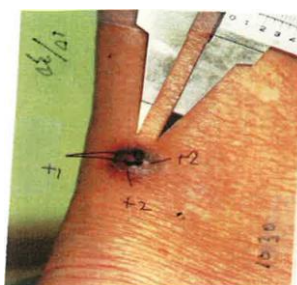
20Oct started AWG (codes: 003, 289, 324)
black spot, +1

22Oct AWG (codes: 158, 032)
black spot, +2

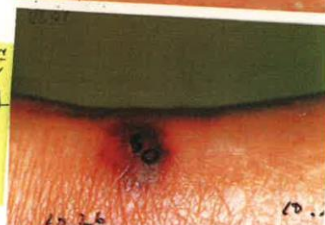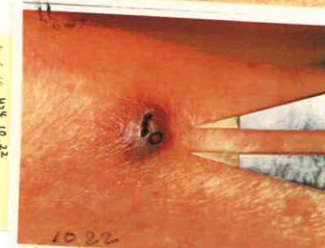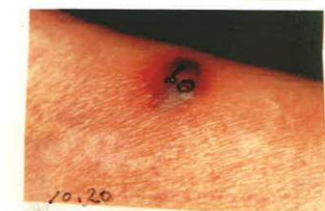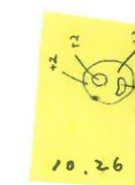

25Oct AWG (codes: 294, 289)

26Oct AWG (codes: 289, 294)

29Oct AWG (code: 289)



30Oct AWG (code: 312)
Deformations of red blood cells were confirmed
by an electro microscopy after AWG treatment



〈 Disease 〉

Melanoma 2 (Intracellular infectious disease)

〈 Symptoms 〉

An infection on the skin, later becomes a melanoma (intercellular infectious disease)

If resection margins are remaining, there is a risk of a recurrence such as tumors

Name : N.K.

Sex : Male

Age : ? y.o.

Clinic/Doctor :
Nishihara Institute

〈 History before and after AWG treatment 〉

2 Nov AWG (code: 289)

5 Nov AWG (code: 289)

8 Nov AWG (code: 293)
A section of the black spot, +1

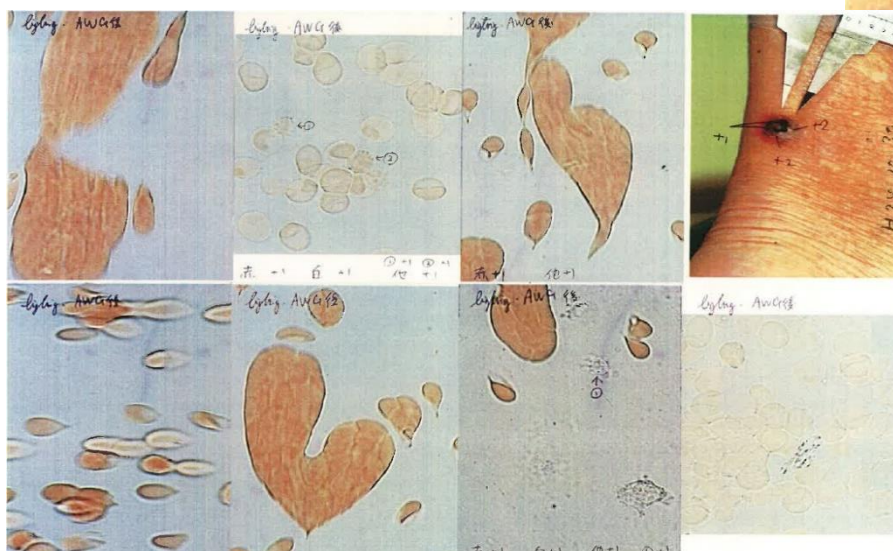
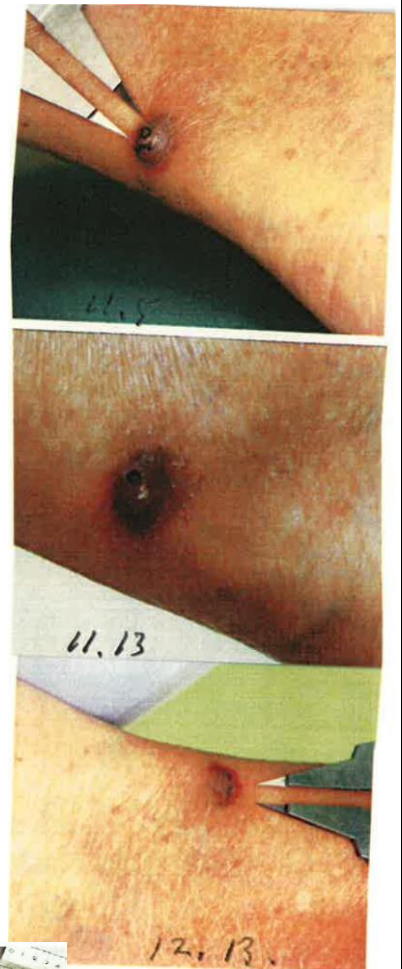
13 Nov AWG (codes: 293, 289)
The spot came off the skin as a scab

14 Nov AWG (code: 158)

19 Nov AWG (codes: 289, 293)

13 Dec AWG (codes: 289, 293)
The melanoma was cured.

Before the AWG treatment, we tested his blood and found a blood figure which we have never seen.



〈 Disease 〉

Breast cancer 1-1

〈 Symptoms 〉

27 May, 2013(H25), she visited our clinic after being explained about the world standard cancer treatments at Shizuoka cancer center. BDORT test result of the left breast was - 2. (refer to the images)

She uses anti-biotics(Josamycin x 2T) and underwent AWG (codes: 289, 293) and thermotherapy (makes body warm) . After these treatments BDORT test showed the level had been improved to + 1

Name : Y.S.

Sex : Female

Age : 69 y.o.

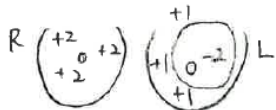
Clinic/Doctor :
Nishihara Institute

〈 History before and after AWG treatment 〉

24 Jun, 2013(H25)

She sometimes feels pain in her left breast.

BDORT test result

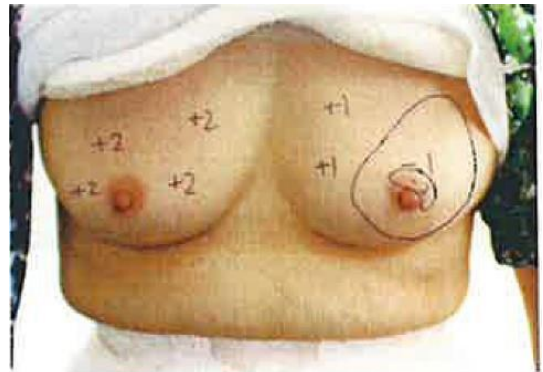


Left breast - 2

She had been taking antibiotics(Flomox(1T)) and conducted;

AWG treatment (codes: 289, 293) and thermotherapy (makes body warm).

After these treatments BDORT test showed the level of the left breast improved to + 2.



29 Jul, 2013(H25)

The pain in the breast was reduced and the lump became smaller.


BDORT test result

Left breast - 1

She had been taking antibiotics(Flomox(1T)) and conducted;

AWG treatment (codes: 143, 262, 289, 293) and thermotherapy (makes body warm).

After these treatments BDORT test showed the level of the left breast improved to + 2.



2 Sep, 2013(H25)

There were no particular problems. The lump had remarkably gone smaller.

BDORT test result

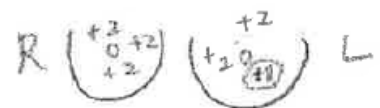
Left breast + 1

She had been taking antibiotics(Flomox(1T)) and conducted;

AWG treatment (codes: 044, 289, 293) and

thermotherapy (makes body warm).

After these treatments BDORT test showed the level of the left breast improved to + 2



〈 Disease 〉

Breast cancer 1-2

〈 Symptoms 〉

27 May, 2013(H25), she visited our clinic after being explained about the world standard cancer treatments at Shizuoka cancer center. BDORT test result of the left breast was - 2. (refer to the images)

She uses anti-biotics(Josamycin x 2T) and underwent AWG (codes: 289, 293) and thermotherapy (makes body warm) . After these treatments BDORT test showed the level had been improved to + 1

Name : Y.S.

Sex : Female

Age : 69 y.o.

Clinic/Doctor :
Nishihara Institute

〈 History before and after AWG treatment 〉

1 Oct, 2013(H25)

She stated the lump had gotten smaller.

BDORT test showed the level was + 2.

She had been taking antibiotics(Flomox(2T)) and conducted;

AWG treatment (code 195,289,293) and thermotherapy (makes body warm).

3 Jul, 2014(H26)

She stated that she caught a cold and had been having a sore throat.

The lump on the left breast had gotten smaller.

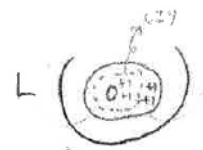
BDORT test result

The area of + 1 is larger

She had been taking antibiotics(Flomox(1T)) and conducted;

AWG treatment (codes: 298, 293, 289) and thermotherapy (makes body warm).

After these treatments BDORT test showed the level of the left breast improved to + 2.



22 Aug, 2014(H26)

She stated the lump had gotten smaller.

BDORT test result

Left breast + 1

She had been taking antibiotics(Flomox(1T)) and conducted;

AWG treatment (codes: 289, 293) and thermotherapy (makes body warm).

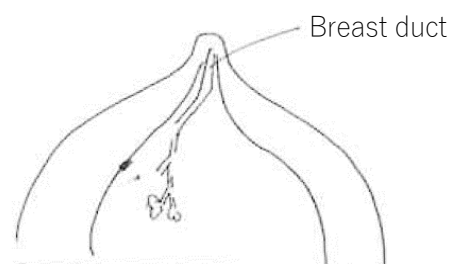
After these treatments BDORT test showed the level of the left breast improved to + 2.



29 Sep, 2014(H26)

BDORT test result: AWG treatment (codes: 289.293.04.

Before: + 1 After: + 2



〈 Disease 〉

Breast cancer 1-3

〈 Symptoms 〉

27 May, 2013(H25), she visited our clinic after being explained about the world standard cancer treatments at Shizuoka cancer center. BDORT test result of the left breast was - 2. (refer to the images)

She uses anti-biotics(Josamycin x 2T) and underwent AWG (codes: 289, 293) and thermotherapy (makes body warm) . After these treatments BDORT test showed the level had been improved to + 1

Name : Y.S.

Sex : Female

Age : 69 y.o.

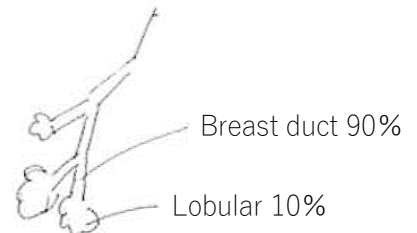
Clinic/Doctor :
Nishihara Institute

〈 History before and after AWG treatment 〉

4 Nov, 2014(H26)

BDORT test result: AWG treatment (codes: 289.293.044)

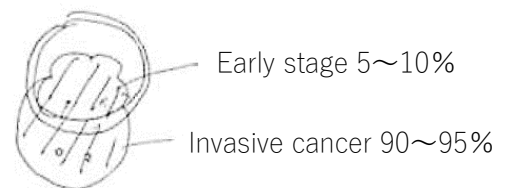
Before: + 1 After: + 2



1 Dec, 2014(H26)

BDORT test result: AWG treatment (codes: 298.007.312)

Before: + 1 After: + 2



6 Jan, 2015(H27)

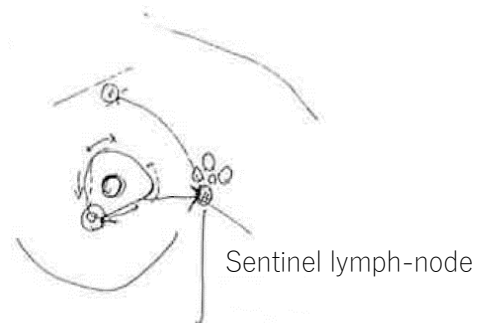
BDORT test result: AWG treatment (codes: 293.289.232.44)

Before: + 1 After: + 2

10 Feb, 205(H27)

BDORT test result: AWG treatment (codes: 293.289.44)

Before: + 1



27 Feb, 2015(H27)

After wearing dentures on 4-7,

BDORT test result of the breast improved to the normal level, + 21

Patient's comment

Since I changed my dentures to correct ones,

I started to chew correctly and It led to my breast cancer being cured.

< Disease >

Varices in legs (Right) 1

< Symptoms > < refer to Picture ① >

12 Jul, 2012(H24) He underwent a BDOT test on his varices and its result was -2.

He had been using antibiotics(Levofloxacin, Josamycin).He had ensured nose breathing (using beauty breathing tape, trainer and nose lift).He underwent an artificial sunlight treatment, but not AWG treatment.

After the treatment, the BDORT"s result was -2 to -1.

Name : K.O.

Sex : Male

Age : 51 y.o.

Clinic/Doctor :
Nishihara Institute

< History before and after AWG treatment >

17 Aug, 2012(H24) Right calf - 2

He was on antibiotics(Levofloxacin, Josamycin)

27 Aug, 2012(H24) Right calf - 2

He was on antibiotics(Levofloxacin) and underwent an artificial sunlight treatment.

01 Oct, 2012(H24) Right calf - 2

He was on antibiotics(Levofloxacin, Josamycin) and underwent an artificial sunlight treatment. After the treatment, the BDORT"s result improved to -1.
He also underwent the organ therapy and the BDORT"s result improved to +1.

19 Nov, 2012(H24) Right calf - 1

< refer to Picture ② >

He was on antibiotics(Levofloxacin) and underwent AWG treatment (code 289.293).

17 Dec, 2012(H24) Right calf + 1

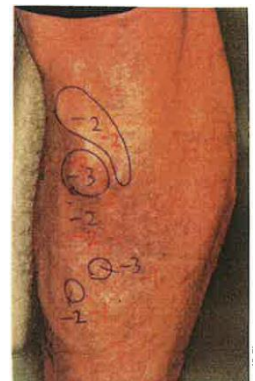
< refer to Picture ③ >

He was on antibiotics(Josamycin) and underwent AWG treatment (code 289.293).

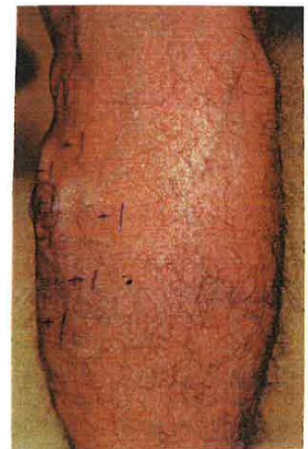After the treatment,
the BDORT"s result improved to +2

12 Feb, 2013(H25) Right calf + 1

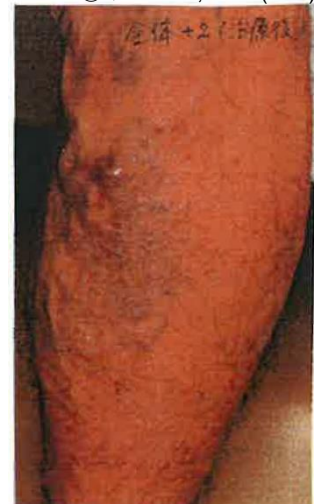He was on antibiotics(Levofloxacin) and underwent AWG treatment (code 289,293)
and the BDORT"s result improved to +2.



Picture① ↑ 12 Jul, 2012(H24)



Picture② ↑ 19 Nov, 2012(H24)



Picture③ ↓ 17 Dec, 2012(H24)

〈 Disease 〉

Varices in legs (Right) 2

〈 Symptoms 〉 < refer to Picture ① >

12 Jul, 2012(H24) He underwent a BDOT test on his varices and its result was - 2.

He had been using antibiotics(Levofloxacin, Josamycin).He had ensured nose breathing (using beauty breathing tape, trainer and nose lift).He underwent an artificial sunlight treatment, but not AWG treatment.

After the treatment, the BDORT"s result was - 2 to - 1.

Name : K.O.

Sex : Male

Age : 51 y.o.

Clinic/Doctor :
Nishihara Institute

〈 History before and after AWG treatment 〉

22 Apr, 2013(H25)

Right calf + 1

He was on antibiotics(Flomox) and underwent AWG treatment (code 289.293.324. 158) and the BDORT"s result improved to + 2.

20 May, 2013(H25)

Right calf + 1

He underwent AWG treatment (code 289.293)

24 Jun, 2013(H25)

Right calf + 1

He was on antibiotics(Flomox) and underwent AWG treatment (code 289.293) and the BDORT"s result improved to + 2.

19 Aug, 2013(H25)

Right calf + 1

He was on antibiotics(Flomox) and carried out an ion therapy and no AWG treatment.

25 Nov, 2013(H25)

Right calf + 1

He was on antibiotics(Flomox) and underwent AWG treatment (code 305.007.289.293) and the BDORT"s result improved to + 2.

14 Jan, 2014(H26)

Right calf + 2

07 Jul, 2014(H26)

Right calf + 1

He was on antibiotics(Minomycin) and underwent AWG treatment (code 312).

10 Nov, 2014(H26)

Right calf + 1


He was on antibiotics(Minomycin) and underwent AWG treatment (code 306.262) and thermotherapy.
The BDORT"s result improved to + 2.

20 Mar, 2015(H27)

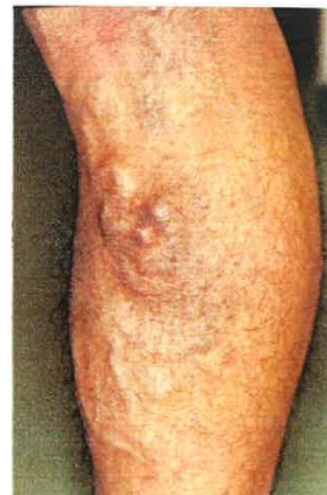Right calf + 2

< refer to Picture ④ >

No recurrence since.

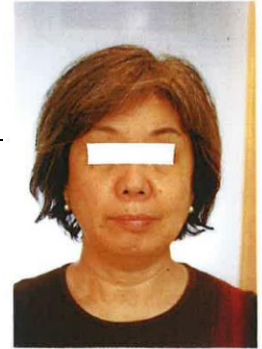

Picture④ ↓ 20 Mar, 2015(H27)



〈 Disease 〉

Breast cancer 2-1



〈 Symptoms 〉

On the 22nd Jan, 2014(H26),

she visited the university hospital and was diagnosed with breast cancer.

Name : K.M.

Sex : Female

Age : 63 y.o.

Clinic/Doctor :
Nishihara Institute

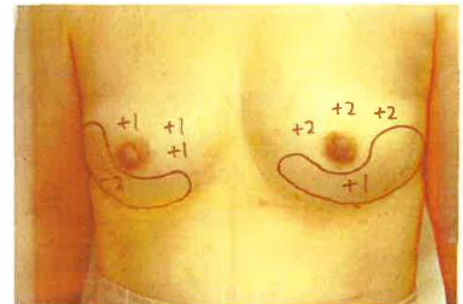
〈 History before and after AWG treatment 〉

23 Jan She underwent AWG treatment and thermotherapy under Dr. Miyanaga.
The BDORT's result of the right breast duct was - 4,
before / - 2, after the treatments.

28 Jan & 16 Feb She had same sessions conducted by Dr. Miyanaga.

1 Mar A metastasis, size 5 mm, on the left breast was found at a different clinic.

17 Mar She visited Nishihara Institute.
She has been on antibiotics(Flomox, Zovirax)
AWG (Code 305.007.324.175.312.118.158.045)
and thermotherapy were performed.
The BDORT's results of all areas were
improved to + 2.



18 Apr The BDORT's results of the both breasts were + 1 before treatments.
She has been on antibiotics(Zovirax).
The AWG(Code 324.158) treatment and thermotherapy were performed.
The BDORT's results of all areas were improved to + 2 .



20 May The BDORT's results of the both breasts were + 1 before treatments
The BDORT's results of all areas were improved to + 2.

23 Jun The BDORT's results of the both breasts (decreased in size)
were + 1 before treatments
She has been on antibiotics(Zovirax).
The AWG(Code 044.158.324) treatment and thermotherapy were performed.
The BDORT's results of all areas were improved to + 2 .



24 Jul The BDORT's results of the both breasts increased to + 2

〈 Disease 〉

Breast cancer 2-2

〈 Symptoms 〉

On the 22nd Jan, 2014(H26),

she visited the university hospital and was diagnosed with breast cancer.

Name : K.M.

Sex : Female


Age : 63 y.o.

Clinic/Doctor :
Nishihara Institute

〈 History before and after AWG treatment 〉

2015(H27)

28 Sep The BDORT"s results of the breast ducts were - 1, right / + 2, left



She has been; on antibiotics(Ciproxan, Geninax tablets, Glycyron),
drinking cold drinks since July; given Zocyn by infusion; thermotherapy
; and homesis(inhailing).

The BDORT"s results improved to + 2.

29 Oct The BDORT"s results of the breast ducts were - 1, right / + 2, left



She has been; on antibiotics(Ciproxan).

The AWG treatment (codes; 158.289.293) and the thermotherapy were performed.

The BDORT"s results improved to + 2.

27 Nov The BDORT"s results of the breast ducts were + 1, right / + 2, left



She has been; on antibiotics(Zovirax, Levofloxacin).

The AWG treatment (codes; 158.175.007) and the thermotherapy were performed.

The BDORT"s results improved to almost + 2.

On a continuous basis, she came for the treatments.

< Disease >

? unknown

< Symptoms >

2012(H24) 4 Dec

First visit with expansions of salivary glands and perilymph, and a sensation of pins and needles sensation in the tongue.

Name : Y. T.

Sex : Female

Age : 43 y.o.

Clinic/Doctor :
Nishihara Institute

< History before and after AWG treatment >

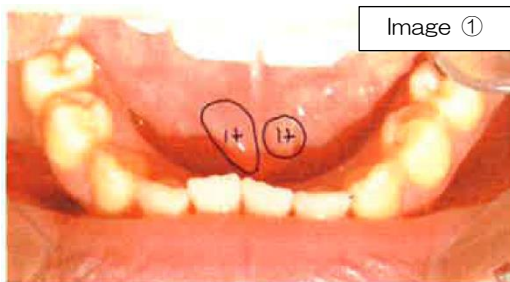
The BDOT results were + 1 on the expansion of right cervical lymph, and sublingual glands under the tongue.

She has been on antibiotics(Levofloxacin).

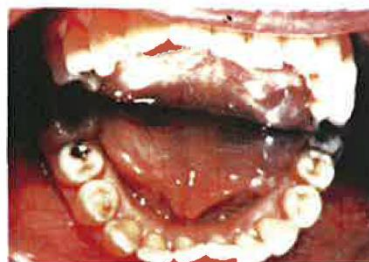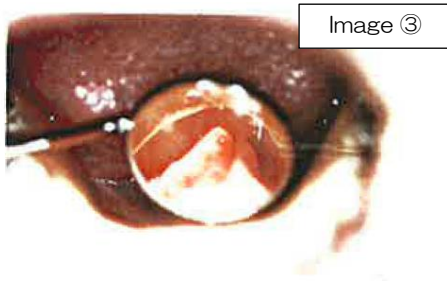
The AWG treatment (codes; 289.293) and the thermotherapy were performed.

After, the BDORT"s results improved to + 2.

< Image ①・② Before >



< Image ③・④ After >



11 Dec The both expansions went away
The BDOT results were improved to + 2

No recurrence since.

〈 Disease 〉

Dry mouth



〈 Symptoms 〉

She was diagnosed with dry mouth and has been taking medicine as prescribed at otolaryngology but she still had strange feelings in her mouth.

Name : Y. T.

Sex : Female

Age : 43 y.o.

Clinic/Doctor :
Nishihara Institute

〈 History before and after AWG treatment 〉

She went to a general dentist/clinic but found no cause for the symptom and it did not get any better. She has started to suffer from an excessive amount of saliva caused by the previous treatment since June 2015(H25), then visited us on the 2nd Jul, 2015(H27).

According to BDORT (Bi-Digital O-ring test), minomycin was effective for use.

She ensured a nose breathing as using nose lifts, beauty breathing tapes and trainers at home. We performed AWG treatment (CODE: 262.117).

The symptom went away after this treatment and no recurrence since.

〈 Disease 〉

Epulis (chronic periodontal infection = intracellular infection)

〈 Symptoms 〉

Name :

Sex : Male

Age : 60 y.o.

Clinic/Doctor :
Nishihara Institute

〈 History before and after AWG treatment 〉

2015(H27)

24 Mar Lower left gum + 1

6 Apr Lower left gum + 1

12 May First sample extraction from lower left gum for
electron microscopic examination Lower left gum + 1 (Clarith 200mg effective)
The granuloma epulis was completely removed

22 May Second sample extraction from the recurrence
at lower left gum for electron microscopic examination

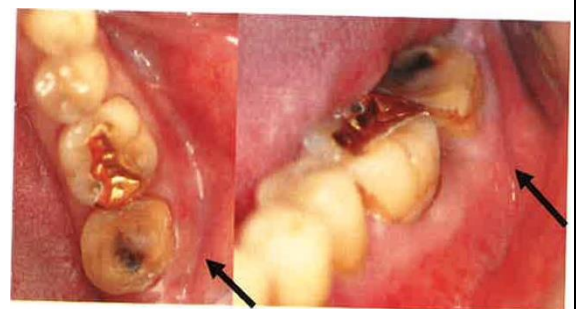
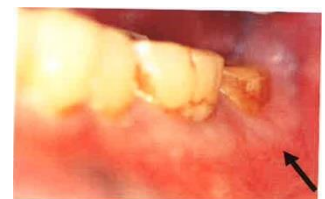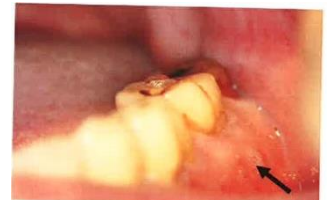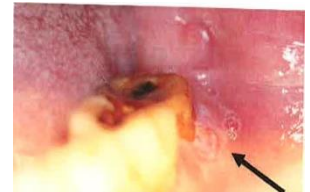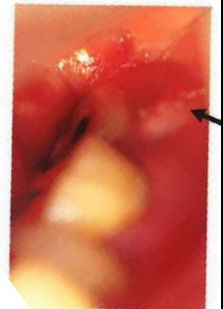
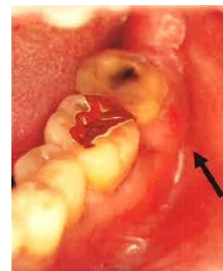
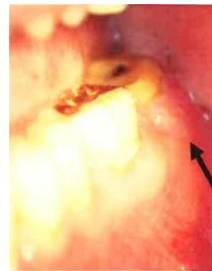
4 Jun The AWG treatment (CODE: 190 · 224) starts

5 Jun A recurrence at lower left gum + 1
He undergoes the AWG treatment everyday

16 Jun The recurrence at lower left gum + 2
The size has shrunk
He undergoes the AWG treatment everyday

7 Jul The recurrence at lower left gum + 2
Completely cured

13 Oct The lesion at lower left gum + 2
There is no recurrences confirmed.



Numbers indicated with +/− are the results of BDORT (Bi-Digital O-ring test).

< Disease >

Thyroid cancer 1

< Symptoms >

In Nov, 2012(H24), she received a notification of the results of the company-provided health check, on the 29 Jan, 2013(H25), she visited one of the hospitals in Oita pref.,
Results of cervical echo cardiograph, multiple thyroid nodules were confirmed.
She was diagnosed with malignant tumors, papillary thyroid cancer, lymph node metastases and thyroid cysts.
No subjective symptoms.

Name : G.H.

Sex : Female

Age : 48 y.o.

Clinic/Doctor : Tajiri general
surgery gastroenterology clinic

< History before and after AWG treatment >

«papillary cancer»

a. 6×6×6mm (right)

b. 14×13×17mm (left)

«metastatic lymph node»

4×11×15mm (right)

5×7×11mm (left)

*It is according to "Report of cervical echo cardiograph report"

I heard about the AWG treatment from my eldest brother. I visited this clinic on 31 Jan, 2013(H25).
First AWG treatment was performed on the same day.

«Course of AWG treatment»

1 day in January 19 days in February 23 days in March
25 days in April 25 in May 8 days in June (Total of 101 days)

She started renting a portable device and treated at home from June, as she requested.

She visited our clinic for a blood test every two months.

«Codes, treatment time, frequency of the AWG treatment»

- ① 7003 (36) Precancerous condition
- ② 7012 (40) Immunity increase
- ③ 7058 (6) General prevention
- ④ 7140 (48) Thyroid adenomas (nodal)

A combination of ①~④ as 1 set. 130 mins, 2 sets / 260 mins

She performed the combination of the codes above several times between AM9:00~PM2:00
or AM8:30~PM2:00.

January	1 day	4 times	※①~④ X 1 set,	2 h 10 m (130 mins)
February	19 days	152 times	※①~④ X 2 sets,	4 h 30 m (260 mins)
March	23 days	184 times	※①~④ X 2 sets,	4 h 30 m (260 mins)
April	25 days	200 times	※①~④ X 2 sets,	4 h 30 m (260 mins)
May	25 days	200 times	※①~④ X 2 sets,	4 h 30 m (260 mins)
June	8 days	64 times	※①~④ X 2 sets,	4 h 30 m (260 mins)

〈 Disease 〉

Thyroid cancer 2

〈 Symptoms 〉

In Nov, 2012(H24), she received a notification of the results of the company-provided health check, on the 29 Jan, 2013(H25), she visited one of the hospitals in Oita pref.,
Results of cervical echo cardiograph, multiple thyroid nodules were confirmed.
She was diagnosed with malignant tumors, papillary thyroid cancer, lymph node metastases and thyroid cysts.
No subjective symptoms.

Name : G.H.

Sex : Female

Age : 48 y.o.

Clinic/Doctor : Tajiri general
surgery gastroenterology clinic

〈 History before and after AWG treatment 〉

Total・ 101 days 804 times

※ The following statements are the results of the AWG treatment with codes ① ~ ④.

※ 30 May, 2013 (H25), The following blood tests were performed at our clinic.

《Blood tests results》

Tests	Results	Units	Reference range
C E A	0.8	ng / mL	under 5.00
T S H	2.06	μlu / mL	0.50 ~ 5.00
F T 3	2.91	pg / mL	2.30 ~ 4.00
F T 4	0.95	ng / dL	0.91 ~ 1.70

The AWG treatments with codes ① ~ ④, 740 times for 93 days

※All of the blood tests' levels were improved to normal, it was the best result.

AWG treatments were continuously performed for preventing purpose after the 1st June, 2013 (H25).

She started the AWG treatment at home after the 8th time in June.

※17 Aug, 2013(H25), a blood test including thyroid hormone at a different clinic in Kumamoto, the results are as below.

《Blood tests results》

Tests	BC counts	Units	Reference range (female)
WBC	3700	/ μL	3500 ~ 9100
RBC	454million	/ μL	3.76 ~ 5million
Hemoglobin	13.2	g / dL	1.3 ~ 15.2
Platelet	183thousand	/ μL	130 ~ 369million

Tests	Results	Units	Reference range
F T 3	2.58	pg / mL	2.30 ~ 4.00
F T 4	0.89	ng / dL	0.90 ~ 1.70
T S H	2.140	μlu / mL	0.50 ~ 5.00

According to the blood tests, every level was improved to be within the reference range.

Effects of AWG treatment led to this successful outcome.

〈 Disease 〉

Brain tumor · Glioma 1

〈 Symptoms 〉

Numbness in hands, feet and face and a swaying feeling.

Name : F.Y.

Sex : Female

Age : 4 y.o.

Clinic/Doctor : Tajiri general
surgery gastroenterology clinic

〈 History before and after AWG treatment 〉

Note: Ambulatory period, 25 Oct, 2014 (H26) ~ 7 Apr, 2015 (H27) ※ AWG treatments only

On the 16th Aug, 2014(H26), she was falling over more than usual while she was playing when visiting my parents' house. Her eyes were out of focus and she was also dribbling. As soon as the parents noticed that she seemed unusual they brought her to Takagi hospital in Yanagikawa city, Fukuoka.

On the same day, she was transferred and admitted emergently to neurosurgery department at Kurume university hospital to look for the cause, from the 16th Aug, 2014(H26) to the 25th Oct, 2014(H26).

She was given 3 months to live.

She started to take chemo therapy during her hospitalization, however the therapy was insignificant.

Her parents decided to let her be discharged and brought her to our clinic on the same day as they left the hospital. We introduced AWG treatment and performed it with ①~⑥ codes plus a. 7012 (immunity). Improvements started to appear from the 2nd day.

She was swaying terribly and dribbling on the first day, but her walking and the facial paralysis seemed a lot better. The parents mentioned that, although a lot of patients worry about what choice of treatments they have after their lives were sentenced, we are very lucky to experience AWG treatments conveniently. Its results were very obvious from the next morning. Even the 3 year old daughter seemed to be very happy with the effects and asked "Can I come to take the treatment everyday so I can go back to kindergarten?"

She happily took the 2.5 hours treatment almost every day from the 25th Oct, 2014(H26) to the 7th Apr, 2015(H27).

≪Code No, time length, frequencies of the AWG treatment≫

- | | |
|-----------------------------------|--|
| ① 7003(36) Precancerous condition | a. 7012(40) Immunity increase |
| ② 7057(18) Cancer | b. 7058(6) Prevention for cancer general |
| ③ 7059(9) Cancer | c. 7064(12) Carcinoma |

〈 Disease 〉

Brain tumor · Glioma 2

〈 Symptoms 〉

Numbness in hands, feet and face and a swaying feeling.

Name : F.Y.

Sex : Female

Age : 4 y.o.

Clinic/Doctor : Tajiri general
surgery gastroenterology clinic

〈 History before and after AWG treatment 〉

- ④ 7069(24) Cerebrospinal general d. 7072(36) Hydrocephalus
⑤ 7115(25) Cancerous disease e. 7251(9) Blood plasma · Lymph
⑥ 7318(24) Tumor general f. 7324(36) Viral disease

a combination of ①～⑥ as 1 set./156 mins (2hrs 36mins)

a combination of a ～ f as 1 set /139 mins (2hrs 19 mins)

She received 1 set each of the treatments between PM1:30～PM4 : 00 or AM10 : 30～PM1 : 00

Monthly frequency(usage?) of AWG treatment

※Days, times, Length of treatment

2014(H26)

October	5days	5times	※all of ①～⑥ codes	2hrs36mins (156mins)
November	30days	30times	※all of ①～⑥ codes	2hrs36mins (156mins)
December	28days	28times	※all of ①～⑥ codes	2hrs36mins (156mins)

2015(H27)

January	26days	26times	※all of a ～ f codes	2hrs19 mins (139mins)
February	29days	29times	※all of a ～ f codes	2hrs19 mins (139mins)
March	31days	62times	※all of a ～ f codes	2hrs19 mins (139mins)
			※all of ①～⑥ codes	2hrs36mins (156mins)
April	6days	36times	※all of a ～ f codes	2hrs19mins (139mins)
			※all of ①～⑥ codes	2hrs19mins (156mins)

Total 155 days 216times

After 155 days / 216 times of AWG treatments, MRI results showed that the tumor had shrunk to 1/4.
This result could have been led by the fact that the patient could concentrate on the treatment for such a long period of time. The reason for this is because her parents were very positive and motivated for AWG treatment.

Once, they had been discouraged that they couldn't find a cure, but AWG treatment gave them hope.

〈 Disease 〉

Prostate cancer 1

〈 Symptoms 〉

On the 7 Feb, 2012 (H24), He was diagnosed with prostate cancer at a certain hospital.
For more tests, he went to Kyusyu university hospital in Fukuoka.
He was recommended to have an operation but he did not feel right about it.
His friend introduced AWG treatment and visited this clinic on the 13 Jun, 2013(H25).

Name : A.H.

Sex : Male

Age : 66 y.o.

Clinic/Doctor : Tajiri general
surgery gastroenterology clinic

〈 History before and after AWG treatment 〉

He was performed AWG treatment with the codes below on the first visit.

◀Code numbers, Time length, Frequency▶

Immunity 7012 (39)

Lower extremity disease 7101 (21)

Prostate 7257 (21)

Cancerous disease 7115 (45)

Cancer general 7058 (6)

※a combination of ① ~ ⑤ as 1 set / 132 mins (2hrs 12mins)

2013 (H25)

June 6 days 30 times ※2 sets of ① ~ ④ 4 hours 30 mins (260 mins)

July 9 days 45 times ※2 sets of ① ~ ④ 4 hours 30 mins (260 mins)

August 10days 50 times ※2 sets of ① ~ ④ 4 hours 30 mins (260 mins)

September 8 days 40 times ※2 sets of ① ~ ④ 4 hours 30 mins (260 mins)

October 9 days 45 times ※2 sets of ① ~ ④ 4 hours 30 mins (260 mins)

November 8 days 40 times ※2 sets of ① ~ ④ 4 hours 30 mins (260 mins)

December 5 days 25 time ※2 sets of ① ~ ④ 4 hours 30 mins (260 mins)

Total 55 days 275 times

2014 (H26)

January 4 days 20 times ※2 sets of ① ~ ④ 4 hours 30 mins (260 mins)

February 5 days 25 times ※2 sets of ① ~ ④ 4 hours 30 mins (260 mins)

March 1 day 5 times ※2 sets of ① ~ ④ 4 hours 30 mins (260 mins)

〈 Disease 〉

Prostate cancer 2

〈 Symptoms 〉

On the 7 Feb, 2012 (H24), He was diagnosed with prostate cancer at a certain hospital.
For more tests, he went to Kyusyu university hospital in Fukuoka.
He was recommended to have an operation but he did not feel right about it.
His friend introduced AWG treatment and visited this clinic on the 13 Jun, 2013(H25).

Name : A.H.

Sex : Male

Age : 66 y.o.

Clinic/Doctor : Tajiri general
surgery gastroenterology clinic

〈 History before and after AWG treatment 〉

〈 Disease 〉

Developmental disorder ▪ Growth disorder 1

〈 Symptoms 〉

Name : T.E.

Sex : Male

Age : 4 y.o.

Clinic/Doctor :
Pyon-Pyon project

〈 History before and after AWG treatment 〉

September, 2016 (H28) First visit
Growth hormone intravenous treatment

From 3 November, 2016 (H28) AWG treatments started

Codes for basics	0003,0012,0324,0058,0056,0171
Codes for head	0069,0180,0318
Codes for intestine	0152,0023,0204,0251,0285,0199,035,0240,0190,0298,0023
Codes for parasites	0010,0241,0249

He received the treatments voluntarily
Basic codes on an almost every day basis
Other codes, alternatively

End of November
He did not catch a cold.
His height increased by 0.7 cm.

End of December
One day, he had a terribly blocked nose and vomited but recovered completely the next day.
His height increased by 0.8 cm.

End of January, 2017 (H29)
He stated to refuse the treatment.
A treatment with codes for head was performed through pads applied on his body.
He was suffering from terrible itchiness, especially the sole of the feet.
His height increased by 0.6cm.

〈 Disease 〉

Developmental disorder ▪ Growth disorder 2

〈 Symptoms 〉

Name : T.E.

Sex : Male

Age : 4 y.o.

Clinic/Doctor :
Pyon-Pyon project

〈 History before and after AWG treatment 〉

February and March

He refused to receive the treatment, so it was performed while he was asleep.

February, His height increased by 0.5 cm.

March, His height increased by 0.4 cm.

End of April

His physical condition was greatly improved

For the first time, he did not catch a cold throughout the entire winter.

His height increased by 0.6 cm.

End of May

In the past, he could barely finish a race on the annual sports day. 2017's sports day, he got the second place and surprised everyone.

His height increased by 0.5 cm.

May Retuned AWG device.

Grandmother's comment

I am very happy that his height increased over 4 cm within half a year without Growth hormone treatment.

His writing, reading and speaking are also improving and it makes the nursery school teacher surprised.

He started to refuse to take the treatment after 3 months because of itchiness.

We (his parents and grandparents) also used the device when he was not using.

Stomach pain and levels of liver and glycosuria are improved. We feel so much better.

〈 Disease 〉

Parkinson's disease ▪ Diabetes1

〈 Symptoms 〉

Name : O.H.

Sex : Male

Age : 78 y.o.

Clinic/Doctor :
Pyon-Pyon project

〈 History before and after AWG treatment 〉

June, 2016 (H28)

First visit

He couldn't walk, change clothes or talk clearly.

October, 2016(H28)

He started the AWG treatment, twice a month

Basics related codes; 0003,0012,0324,0058,0056,0318,0009

Head related codes;

0069, 0305,0318,0239,0023,0025,0295,0030

Glycosuria related codes; 0240, 0095,0115,0289,0293

Local region related codes;

0152,0023,0204,0251,0285,0199,0135,0289,0293,0115

Parasites related codes; 0010,0241,0249

End of October

Swelling in feet was improved

He commented his body was light and feels well.

End of November

He could put on trousers by himself while standing

Trembling in hands was improved

End of December

His condition seemed to be subsided so he consulted with Dr. Shiraki about the current medication and stopped certain ones.

End of January, 2017 (H29)

He was able to stand on one leg for 1 min 40 seconds

(Right 10 sec, Left 18 sec, before)

He finally realized the possibilities.

He surprised everyone at his day care center by showing everyone jumping over a small brook about 80cm, in front of the center.

〈 Disease 〉

Parkinson's disease ▪ Diabetes2

〈 Symptoms 〉

Name : O.H.

Sex : Male

Age : 78 y.o.

Clinic/Doctor :
Pyon-Pyon project

〈 History before and after AWG treatment 〉

End of February His condition seemed to be subsided even more
He had been treating himself with Parkinson's code only for a while. We explained and told him to use the codes originally suggested.

End of March His body movements had got even better, he was able to go out more including going out for local election support.

End of April Termination of AWG treatment

His daughter's comment;

Because of AWG treatment, he is able to do basic activities such as changing, bathing and toileting without any support now. However, I feel frustrated that he doesn't want to stop taking medication. Now, he can go out for drinks with his friends several times a week and it makes him look happy.

〈 Disease 〉

Uveitis, Tumors, Inflammation of skin and organ

〈 Symptoms 〉

- Uveitis on both eyes (90% of visual field is defected) • Nephritis (multiple neoplastic)
- Dermatitis (itching) • Lung tumor • Gastritis (unable to intake food)
- Enteritis • Urination disorders (no micturition)

Name : K.N.

Sex : Female

Age : 45 y.o.

Clinic/Doctor :
Pyon-Pyon project

〈 History before and after AWG treatment 〉

On the 1st September 2017 (H29), ORION checkup, AWG treatment start.

As a result of the checkup, sarcoidosis was suspected.

Dr. Shiraki determined the result by confirming medical history and symptoms with the patient.

Basics related codes	0003,0012,0324,0058,0056,0318
Skin related codes	0109,0161,0116,0062
Lung related codes	0253,0317,0318
Local region related codes	0152,0137,0104,0184,0182,0318,0204, 0251,0115,0285,0199,0135,0023,0016
Kidneys related codes	0190,0298,0023,0318,0246,0301,0115
Head related codes	0069,0305,0318,0225,0230,0311,0023
Eyes related codes	0120,0115,0023,0139,0315,0225,0141,0218,0233,0311
Bacteria related codes	0289,0293,0032,0062

7hours for 4 to 5 days a week or 14 hours with 2 devices as many days as possible

Before the treatment, 90% of her visual field was defected because of uveitis, but it has been almost recovered.

Color deficiency (black and white) on right eye, edema on legs, urination disorders have completely been recovered. Skin condition improved soon after the treatment but itchiness came back during nights.

Almost every tumor in uterine and ovaries have gone

Her appetite has increased but no solid food.

Her family and colleagues say she used to look pale but now she looks so well and her body weight also became the heaviest it has ever been.

The itchiness was distressing her the most and kept her awake during the night.

Overall, she feels all of the symptoms have been improved.

However, uncertainty remains so she continues the AWG treatment

〈 Disease 〉

Angina ▪ Systemic lupus

〈 Symptoms 〉

She had always been tired since she was a kid, therefore she was not good at exercising, always catching colds and staying in bed and unable to attend a school. Her gastro intestine was weak. She was losing weight because of a loss in appetite. After getting married, her tiredness increased. She was diagnosed with angina. She consulted a neurologist and was prescribed with tranquilizers, antidepressants and sleep inducing drugs. The tiredness did not improved with the medication, so her and her husband moved from Tokyo to her parents' house in Fukuoka. She has spent most of the time in bed for the last 3 years.

Name : T.Y.

Sex : Female

Age : 44 y.o.

Clinic/Doctor :
Pyon-Pyon project

〈 History before and after AWG treatment 〉

February 2017 (H29)

First visit

She started AWG treatment as systemic lupus erythematosus was strongly suspected.

Basics related codes 0003,0012,0324,0058,0056,0009

Heart related codes 0152,0023,0221,0039,0015

Gastrointestinal codes 0137,0067,0021,0104,0184,0182

Head related codes 0069,0305,0316,0318,0225,0230,0023

Kidney related codes 0190,0298,0039,0015,0025,0115

Body related codes 0204,0251,0285,0199,0135,0240

Bacteria related codes 0289,0293,0032,0062

She never forgot to perform the treatment with these 2 codes; 0056,0009 every night repeatedly.

Day 2 She felt an overall improvement in her body. She was surprisingly vibrant in the morning.

Day 3 She had a high temperature at 38°C but did not lose her appetite

Day 7 Her appetite increased. She started to be able to do house chores little by little.

After 1 month, due to a terrible itchiness, she started to apply the treatment's pads on her soles while sleeping.

After 2 months, although the itchiness remains, she was able to go out frequently, even for shopping.

After 3 months, she could go on a small trip with her family for the first time in 10 years.

Currently, she looks well, speaks loud, and gained 5 kg. She can do every house chore now.

The whole family has been uplifted.

The patient's voice;

I am happy every day, this is the best I have felt in my life. My husband left his job. Instead, he is going to obtain a qualification so that he can support me by my side.

< Disease >

Gallbladder cancer

< Symptoms >

2 Dec, 2013 She had a symptom of jaundice so she visited T hospital for a consultation.
She was diagnosed with gallbladder cancer.

May 2014 Metastases in gallbladder, spleen, duodenal, and lung were surgically operated.
She underwent radiation therapy 23 times and chemo therapy twice.

Nov, 2015 She was hospitalized due to intestinal obstruction.
More metastases were found in the liver and lung, she tried various natural remedies.

Name : M.Y.

Sex : Female

Age : 68 y.o.

Clinic/Doctor :
Pyon-Pyon project

< History before and after AWG treatment >

- Bowel pain significantly improved when AWG treatment had just finished at our clinic, but the pain came back by the time she had returned home.

No changes in the metastases of liver and lung.

Later on, she started a home therapy with the rental AWG device.

- She has been using pain related codes as well as local related codes.

The greatest attraction is the ability to relieve pain and fight whilst coexisting with cancer.

Patient's comment

- I feel less pain and relaxed during the AWG treatment.

Although I get muscle pain after excising too long due to a weakness of physical and muscle strength, I recover by performing AWG with muscle related codes and recovery related codes.

〈 Disease 〉

Pancreatic cancer (metastases ver, lung,peritoneal)

〈 Symptoms 〉

November, 2015 He was diagnosed with pancreatic cancer at S hospital in Fukuoka city, Fukuoka pref.
December, 2015 He underwent chemotherapy.
March, 2016 Metastases to liver, lung and peritoneal were detected. She was given 3 months to live and recommended palliative treatment.

Name : H.K.

Sex : Male

Age : 53 y.o.

Clinic/Doctor :
Pyon-Pyon project

〈 History before and after AWG treatment 〉

22 May, 2016 He started the AWG treatment.
He had jaundice.

He did not have an appetite and could not eat solid food at all.

He has been repeatedly vomiting and having diarrhea.

He was also suffering from back pain. However, the pain started to relive right after the AWG treatment and gradually removed completely in a week.

His appetite came back from the 4th day and within a week he was able to eat normal.

Jaundice healed completely and the ascites pain was also almost gone after 2 weeks, depending on his condition and diet for the day.

July, 2016 His conditions including appetite, mind and body, were met. He admitted himself to hospital for surgery on the ascites metastases.
After the surgery, he was extremely exhausted and also having pain.
After he was discharged from the hospital, we performed AWG treatment on him for his pain. The pain started to ease by the 3rd day.

Aug, 2016 He admitted himself into A hospital for Palliative treatment by AWG.

Comments

At the beginning of his hospitalization, he was weak and distressful because of the pain he had all over his body.

Back pain was removed in 1 week, but the ascites pain took 1 month to be removed completely.

〈 Disease 〉

Adenoid cystic carcinoma

〈 Symptoms 〉

May 2005 She was diagnosed with adenoid cystic carcinoma at H hospital in Fukuoka city, Fukuoka pref.

June 2005 Metastases to lung and liver were found. Surgical operation and over 60 times of radiation treatments were carried out until Oct 2011. She was given 3 months to live.
She resigned from her job and returned to her parents' home.

Name : M.T.

Sex : Female

Age : 47 y.o.

Clinic/Doctor :
Pyon-Pyon project

〈 History before and after AWG treatment 〉

Jan 2015 She started to undergo AWG treatment from the 7th until the 14th, total of 28 sessions.
▪ She was suffering from terrible pain in thoracic vertebra and lumbar spine.
She did not feel the pain during the treatment, which was performed while she was attached with oxygen inhaler. She could breathe easier, laughed and chatted with people surrounding her. Especially, the pain around the bone and the tightening feeling of body had eased.

May 2016 She switched to home AWG treatment

Comments

Since I was diagnosed with cancer 12 years ago,

I have no regrets that I had been taking treatments I wanted.

I know "pain relief code" relaxes me.

I have learnt which codes to use depending on the health condition.

Lately, I treat myself right before the pain comes and it helps me feel much more relaxed.

〈 Disease 〉

Breast cancer (lymph nodes, skin, bones, pleural and lung metastases)

〈 Symptoms 〉

Jan 2013 She was diagnosed with breast cancer.
Feb 2013 The whole breast was removed at H Hospital in Fukuoka city, Fukuoka prefecture. She underwent chemo therapy.
Aug 2013 Metastasis to lymph node was found and operated on at Kumamoto hospital. She underwent chemo therapy.
Dec 2014 Metastases to bones, skin and pleural were found. She was told she has 3 months to live.
Jan 2015 She started various natural remedies and immunotherapy.

Name : Y.H.

Sex : Female

Age : 54 y.o.

Clinic/Doctor :
Pyon-Pyon project

〈 History before and after AWG treatment 〉

Feb 2015 She started AWG treatment. Pain from the skin tension, coughing, breathing and a pain in the ribs were all improved.

Mar 2015 She switched to AWG home treatment.
After one month, all of the pains mentioned above continually improved.

Jul 2015 The values on her blood test improved and they impressed her immunotherapy doctor.

Aug 2015 She performed the molecularly-targeted therapy at S hospital in Fukuoka city, Fukuoka prefecture.

Comments

- The greatest thing about the AWG treatment is that all of the pain has been relieved.
I became really well at one point and making everyone worried by saying I wanted to work as a part-timer.
I was having an extremely hard time and could barely sleep due to the uncomfortableness of the skin tension from the operation, the tumors on the skin and the intense pain I used to get from the pleural metastasis. Currently, all that pain has gone away by using any codes on AWG so I don't need to rely on pills anymore.

Clinics and representative doctor adopting the device (alphabetical order)

Amagi Clinic ... Shigefumi Shibata

Futakuchi Children's Hospital ... Soichiro Futakuchi

Kashima Dental Clinic ... Takamasa Kashima

Kuwano Suzuki Naika Clinic ... Satoru Suzuki

LLP Pyon-Pyon Project ... Ruiko Shiraki

Masuda Dental Clinic ... Kazuhito Masuda

Mitaka Healthcare Clinic ... Takashi Fukushima

Mobara Function Clinic ... Yutaka Ito

Namba Wave Clinic ... Yoshiharu Namba

Nishihara Institute ... Katsunari Nishihara

Oita Rehabilitation Hospital ... Hidetoshi Tachibana

Saranuma Clinic ... Tooru Fujita

Takeda Gastrointestinal Clinic... Yoshio Takeda

Tsutsujigaoka Clinic ... Kiichi Ito

〈 Disease 〉

Developmental disorder ▪ Growth disorder 1

〈 Symptoms 〉

Name : T.E.

Sex : Male

Age : 4 y.o.

Clinic/Doctor :
Pyon-Pyon project

〈 History before and after AWG treatment 〉

September, 2016 (H28) First visit
Growth hormone intravenous treatment

From 3 November, 2016 (H28) AWG treatments started

Codes for basics	0003,0012,0324,0058,0056,0171
Codes for head	0069,0180,0318
Codes for intestine	0152,0023,0204,0251,0285,0199,035,0240,0190,0298,0023
Codes for parasites	0010,0241,0249

He received the treatments voluntarily
Basic codes on an almost every day basis
Other codes, alternatively

End of November
He did not catch a cold.
His height increased by 0.7 cm.

End of December
One day, he had a terribly blocked nose and vomited but recovered completely the next day.
His height increased by 0.8 cm.

End of January, 2017 (H29)
He stated to refuse the treatment.
A treatment with codes for head was performed through pads applied on his body.
He was suffering from terrible itchiness, especially the sole of the feet.
His height increased by 0.6cm.

〈 Disease 〉

Developmental disorder ▪ Growth disorder 2

〈 Symptoms 〉

Name : T.E.

Sex : Male

Age : 4 y.o.

Clinic/Doctor :
Pyon-Pyon project

〈 History before and after AWG treatment 〉

February and March

He refused to receive the treatment, so it was performed while he was asleep.

February, His height increased by 0.5 cm.

March, His height increased by 0.4 cm.

End of April

His physical condition was greatly improved

For the first time, he did not catch a cold throughout the entire winter.

His height increased by 0.6 cm.

End of May

In the past, he could barely finish a race on the annual sports day. 2017's sports day, he got the second place and surprised everyone.

His height increased by 0.5 cm.

May Retuned AWG device.

Grandmother's comment

I am very happy that his height increased over 4 cm within half a year without Growth hormone treatment.

His writing, reading and speaking are also improving and it makes the nursery school teacher surprised.

He started to refuse to take the treatment after 3 months because of itchiness.

We (his parents and grandparents) also used the device when he was not using.

Stomach pain and levels of liver and glycosuria are improved. We feel so much better.

〈 Disease 〉

Parkinson's disease ▪ Diabetes1

〈 Symptoms 〉

Name : O.H.

Sex : Male

Age : 78 y.o.

Clinic/Doctor :
Pyon-Pyon project

〈 History before and after AWG treatment 〉

June, 2016 (H28)

First visit

He couldn't walk, change clothes or talk clearly.

October, 2016(H28)

He started the AWG treatment, twice a month

Basics related codes; 0003,0012,0324,0058,0056,0318,0009

Head related codes;

0069, 0305,0318,0239,0023,0025,0295,0030

Glycosuria related codes; 0240, 0095,0115,0289,0293

Local region related codes;

0152,0023,0204,0251,0285,0199,0135,0289,0293,0115

Parasites related codes; 0010,0241,0249

End of October

Swelling in feet was improved

He commented his body was light and feels well.

End of November

He could put on trousers by himself while standing

Trembling in hands was improved

End of December

His condition seemed to be subsided so he consulted with Dr. Shiraki about the current medication and stopped certain ones.

End of January, 2017 (H29)

He was able to stand on one leg for 1 min 40 seconds

(Right 10 sec, Left 18 sec, before)

He finally realized the possibilities.

He surprised everyone at his day care center by showing everyone jumping over a small brook about 80cm, in front of the center.

〈 Disease 〉

Parkinson's disease ▪ Diabetes2

〈 Symptoms 〉

Name : O.H.

Sex : Male

Age : 78 y.o.

Clinic/Doctor :
Pyon-Pyon project

〈 History before and after AWG treatment 〉

End of February His condition seemed to be subsided even more
He had been treating himself with Parkinson's code only for a while. We explained and told him to use the codes originally suggested.

End of March His body movements had got even better, he was able to go out more including going out for local election support.

End of April Termination of AWG treatment

His daughter's comment;

Because of AWG treatment, he is able to do basic activities such as changing, bathing and toileting without any support now. However, I feel frustrated that he doesn't want to stop taking medication. Now, he can go out for drinks with his friends several times a week and it makes him look happy.

〈 Disease 〉

Uveitis, Tumors, Inflammation of skin and organ

〈 Symptoms 〉

- Uveitis on both eyes (90% of visual field is defected) • Nephritis (multiple neoplastic)
- Dermatitis (itching) • Lung tumor • Gastritis (unable to intake food)
- Enteritis • Urination disorders (no micturition)

Name : K.N.

Sex : Female

Age : 45 y.o.

Clinic/Doctor :
Pyon-Pyon project

〈 History before and after AWG treatment 〉

On the 1st September 2017 (H29), ORION checkup, AWG treatment start.

As a result of the checkup, sarcoidosis was suspected.

Dr. Shiraki determined the result by confirming medical history and symptoms with the patient.

Basics related codes	0003,0012,0324,0058,0056,0318
Skin related codes	0109,0161,0116,0062
Lung related codes	0253,0317,0318
Local region related codes	0152,0137,0104,0184,0182,0318,0204, 0251,0115,0285,0199,0135,0023,0016
Kidneys related codes	0190,0298,0023,0318,0246,0301,0115
Head related codes	0069,0305,0318,0225,0230,0311,0023
Eyes related codes	0120,0115,0023,0139,0315,0225,0141,0218,0233,0311
Bacteria related codes	0289,0293,0032,0062

7hours for 4 to 5 days a week or 14 hours with 2 devices as many days as possible

Before the treatment, 90% of her visual field was defected because of uveitis, but it has been almost recovered.

Color deficiency (black and white) on right eye, edema on legs, urination disorders have completely been recovered. Skin condition improved soon after the treatment but itchiness came back during nights.

Almost every tumor in uterine and ovaries have gone

Her appetite has increased but no solid food.

Her family and colleagues say she used to look pale but now she looks so well and her body weight also became the heaviest it has ever been.

The itchiness was distressing her the most and kept her awake during the night.

Overall, she feels all of the symptoms have been improved.

However, uncertainty remains so she continues the AWG treatment

〈 Disease 〉

Angina ▪ Systemic lupus

〈 Symptoms 〉

She had always been tired since she was a kid, therefore she was not good at exercising, always catching colds and staying in bed and unable to attend a school. Her gastro intestine was weak. She was losing weight because of a loss in appetite. After getting married, her tiredness increased. She was diagnosed with angina. She consulted a neurologist and was prescribed with tranquilizers, antidepressants and sleep inducing drugs. The tiredness did not improved with the medication, so her and her husband moved from Tokyo to her parents' house in Fukuoka. She has spent most of the time in bed for the last 3 years.

Name : T.Y.

Sex : Female

Age : 44 y.o.

Clinic/Doctor :
Pyon-Pyon project

〈 History before and after AWG treatment 〉

February 2017 (H29)

First visit

She started AWG treatment as systemic lupus erythematosus was strongly suspected.

Basics related codes 0003,0012,0324,0058,0056,0009

Heart related codes 0152,0023,0221,0039,0015

Gastrointestinal codes 0137,0067,0021,0104,0184,0182

Head related codes 0069,0305,0316,0318,0225,0230,0023

Kidney related codes 0190,0298,0039,0015,0025,0115

Body related codes 0204,0251,0285,0199,0135,0240

Bacteria related codes 0289,0293,0032,0062

She never forgot to perform the treatment with these 2 codes; 0056,0009 every night repeatedly.

Day 2 She felt an overall improvement in her body. She was surprisingly vibrant in the morning.

Day 3 She had a high temperature at 38°C but did not lose her appetite

Day 7 Her appetite increased. She started to be able to do house chores little by little.

After 1 month, due to a terrible itchiness, she started to apply the treatment's pads on her soles while sleeping.

After 2 months, although the itchiness remains, she was able to go out frequently, even for shopping.

After 3 months, she could go on a small trip with her family for the first time in 10 years.

Currently, she looks well, speaks loud, and gained 5 kg. She can do every house chore now.

The whole family has been uplifted.

The patient's voice;

I am happy every day, this is the best I have felt in my life. My husband left his job. Instead, he is going to obtain a qualification so that he can support me by my side.